

An introduction to imaging of orbital pathology

December 4, 2018: Soraya Robinson, Vienna/AT

Prof. Soraya Robinson

Prof. Robinson was trained at the university hospital in Vienna, where she worked until 2001. After four years at the university hospital in Helsinki she returned to Vienna and has since been working as a general radiologist with a special focus on head and neck radiology in a big imaging centre.

She is presently leading the head and neck radiology working group in Austria and has been on the Executive Committee of the European Society for Head and Neck Radiology for several years. She has been active in the European Society of Radiology as Head and Neck Subcommittee chair of the ECR and part of the Programme Planning Committee of the ECR establishing and leading the Case Based Diagnosis Training at the ECR for the last couple of years. Her reviewing activity involves oral and EPOS abstracts at the ECR, as well as abstracts at the ESHNR and manuscripts for several high impact radiological journals.



Abstract

Optimizing examination technique and familiarity with most important anatomic landmarks of the conical orbit are prerequisites for correct recognition of pathology.

The aim of this lecture is to familiarize the audience with the significance of orbital compartments, guide through the strengths of various imaging modalities, to cover tricks and tips, how to maximize their outcome and to provide a roadmap for interpretation avoiding typical pitfalls.

The optic nerve is part of the central nervous system, covered by dura, arachnoid and pia and enters the orbit together with the ophthalmic artery through the optic canal.

Superolaterally is the superior orbital fissure with cranial nerves, III, IV, V1 and VI, as well as the superior ophthalmic vein. The posterior opening at the inferolateral border of the orbit is the inferior orbital fissure for the maxillary nerve and the inferior ophthalmic vein.

Innervation and function of the cone forming extraocular muscles will be addressed and the importance of differentiation extraconal, conal and intraconal disease will be emphasized.

Bulb and lacrimal gland pathology, as well as relevant diseases of neighbouring structures, such as paranasal sinuses, bone and meninges followed by postoperative findings are an integral part of the lecture.

Characteristic features of most common entities will be covered enabling the participants to analyze the orbit accordingly and pick up pathognomonic signs.

Learning Objectives

1. To describe orbital anatomy and key anatomic structures relevant for a compartment based differential diagnosis
2. To review the imaging aspect of common and less common orbital masses and inflammatory conditions affecting the orbit
3. To highlight potential pitfalls and how to avoid missing out on relevant pathology
4. To provide the essential tools for a comprehensive radiologic report

Teaser

57-year old female patient with decreased visual acuity on her right side

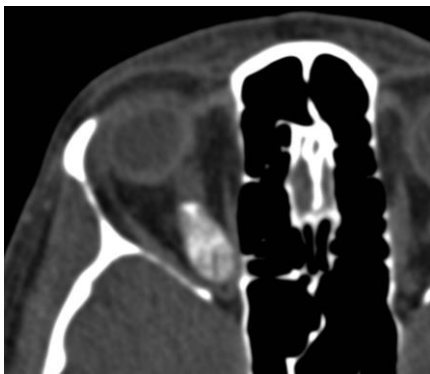

Figure 1a: transverse non-enhanced CT, soft tissue window

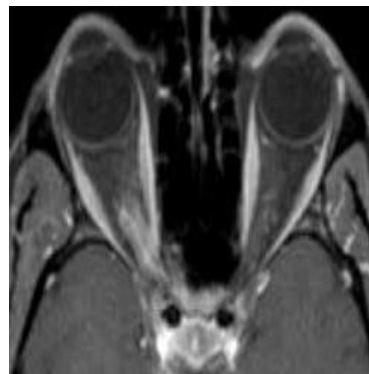


Figure 1b: transverse, fat-suppressed, contrast enhanced T1 weighted image

Test Your Knowledge

Only one answer is correct.

1. Orbital calcifications are pathognomonic for
 - a. grave's disease
 - b. retinoblastoma
 - c. optic sheath meningeoma
 - d. cavernous hemangioma
 - e. optic glioma
2. Several compartments can be affected in
 - a. lymphangioma
 - b. IgG 4 related disease
 - c. lymphoma
 - d. optic glioma
 - e. retinal detachment

3. The oculomotoric nerve innervates
 - a. all rectus muscles
 - b. medial, superior, inferior rectus and superior oblique muscle
 - c. lateral, superior, inferior rectus and inferior oblique muscle
 - d. medial, superior, inferior rectus muscle, inferior oblique and levator palpebrae muscle
 - e. lateral, superior, inferior rectus and superior oblique muscle

4. Superior orbital fissure houses
 - a. cranial nerves III, IV, V2, VI and superior ophthalmic vein
 - b. cranial nerves III, IV, V1, VI and superior ophthalmic vein
 - c. cranial nerves III, IV, V1, VI and ophthalmic artery
 - d. cranial nerves III, IV, V2, VI and ophthalmic artery
 - e. cranial nerves III, IV, V3, VI and superior ophthalmic vein

5. Grave's disease
 - a. is characterized by elongation of the bulb
 - b. causes exophthalmus due to thickening of extraocular muscles
 - c. affects tendinous insertions of extraocular muscles
 - d. most commonly involves the lateral and superior rectus muscles
 - e. initially typically involves the inferior and medial rectus muscle